Chinese Medical Sciences Journal 41 (2026) 115–118

Contents lists available at ScienceDirect

Chinese Medical Sciences Journal

journal homepage: https://www.keaipublishing.com/en/journals/chinese-medical-sciences-journal/

Case report

Dental management of a 3-year-old boy with glucose-6-phosphate dehydrogenase deficiency under general anesthesia: A case report

Lin Ma[a,*], Xiu-Hua Zhang[b], Shu-Yu Zheng[a], Xin-Xin Wang[c], Shuang Wang[c]

[a] Department of Dentistry, Peking Union Medical College Hospital, Chinese Academy of Medical Sciences & Peking Union Medical College, Beijing 100730, China
[b] Department of Anesthesiology, Peking Union Medical College Hospital, Chinese Academy of Medical Sciences & Peking Union Medical College, Beijing 100730, China
[c] International Medical Services, Peking Union Medical College Hospital, Chinese Academy of Medical Sciences & Peking Union Medical College, Beijing 100730, China

ARTICLE INFO

Keywords:
Glucose-6-phosphate dehydrogenase deficiency
Pedodontics
Dental treatment
General anesthesia

ABSTRACT

Glucose-6-phosphate dehydrogenase (G6PD) deficiency is a common X-linked recessive disorder that increases susceptibility to oxidative hemolysis, presenting potential safety concerns for pediatric dental treatment under general anesthesia. This case report describes a 3-year-old male patient from northern China, who was diagnosed with G6PD deficiency and concurrent severe early childhood caries, with a notable history of acetaminophen-induced hemolysis. A multidisciplinary preoperative consultation was conducted to formulate an individualized treatment protocol. Anesthesia was induced with sevoflurane and maintained by propofol combined with remifentanil. Full-mouth dental rehabilitation was successfully completed using articaine for local anesthesia, accompanied by rigorous perioperative monitoring. The patient achieved favorable outcomes without hemolytic or anesthetic complications during the 18-month follow-up. This case provides practical clinical reference for perioperative medication strategies and individualized safety management in high-risk pediatric patients with G6PD deficiency undergoing dental treatment.

1. Introduction

Glucose-6-phosphate dehydrogenase (G6PD) deficiency is the most common enzyme defect in humans, affecting over 400 million individuals worldwide, with high endemic prevalence in Africa, Southeast Asia, and the Mediterranean region.[1–3] In China, its prevalence exhibits a prominent south-high and north-low epidemiological distribution, with national newborn screening data reporting 1.94% in South China versus only 0.08% in North China.[4] G6PD deficiency impairs erythrocyte antioxidant defense, predisposing affected individuals to acute hemolytic anemia when exposed to exogenous oxidative triggers, including specific medications, infections, and physiological stressors such as surgery and invasive procedures.[2]

Children with severe early childhood caries often require full-mouth dental rehabilitation under general anesthesia, which poses clinical risks for those with G6PD deficiency. Untreated dental infectious lesions and anesthesia/procedure-related physiological stress are potential triggers for acute hemolytic crises in this vulnerable population. However, consensus on anesthetic drug selection and perioperative management for this population remain limited. Herein, we report the case of a G6PD-deficient boy from northern China who received comprehensive dental treatment under general anesthesia, and summarize key perioperative safety considerations and practical strategies for managing this high-risk population.

2. Case presentation

A 3-year-old male patient, with a height of 90 cm and weight of 13 kg, presented to the Department of Dentistry at Peking Union Medical College Hospital, with multiple dental caries. He had a history of recurrent idiopathic hemolytic anemia since infancy and received a molecular diagnosis of G6PD deficiency at 2 years of age. Whole-exome high-throughput sequencing combined with systematic bioinformatic monogenic variant analysis identified a pathogenic hemizygous variant c.1160 G>A in the *G6PD* gene, consistent with his intermittent hemolytic episodes. The patient was born full-term in Shenyang, Liaoning province, with a birth weight of 2.8 kg, and his parents were phenotypically normal with no evidence of G6PD deficiency. No specific medication was prescribed for G6PD deficiency. The family received standardized counseling on avoiding oxidative drugs, infections, and other potential hemolytic triggers for long-term disease management.

Intraoral examination revealed extensive dental caries, poor oral hygiene, and moderate plaque accumulation (Fig. 1A). The parents reported mild dental pain and occasional gingival bleeding during tooth-

* Corresponding author.
E-mail: linmaxy@sina.com (L. Ma).

https://doi.org/10.1016/j.cmsj.2026.09.001

Available online 29 October 2026
1001-9294/© 2026 The Authors. Publishing Services by Elsevier B.V. on behalf of KeAi Communications Co. Ltd. This is an open access article under the CC BY-NC license (http://creativecommons.org/licenses/by-nc/4.0/)

brushing. Preoperative radiographs confirmed multiple carious lesions in primary teeth, with no apical or furcation infections (Fig. 1D).

According to the Frankl Behavioral Rating Scale, the patient was classified as Grade 1 (completely uncooperative), with no prior history of anesthesia or sedation for dental treatment. Thus, general anesthesia was deemed necessary.

Preoperative evaluation showed no pallor, jaundice, or abnormal airway findings. Routine blood tests and liver/kidney function assays were within normal ranges. Preoperative enzymatic testing revealed G6PD activity at 48%–70% of the normal reference range, corresponding to WHO Class III G6PD deficiency.[2] A multidisciplinary team involving pediatric hematologists and anesthesiologists was conducted to optimize the treatment plan, with emphasis on anesthetic safety and hemolysis prevention. The team reached a consensus: actively eliminate oral infectious lesions, strictly avoid all oxidative hemolytic triggers, administer low-oxidative anesthetics, and provide 6 hours of postoperative monitoring. The finalized anesthetic protocol consisted of sevoflurane for induction, with propofol and remifentanil for maintenance. Written informed consent was obtained from the parents after detailed explanation of the procedure, risks, and benefits.

Dental treatment included pulp therapy, restorative procedures, and stainless steel crown placement (Fig. 2A), with 1.0 mL of articaine administered for local anesthesia. The procedure was completed without intraoperative complications. Postoperatively, the patient was monitored for 6 hours for signs of hemolysis, with pediatric follow-up scheduled 3 days later. The parents received oral hygiene instruction to prevent recurrent caries. Regular follow-ups and quarterly professional fluoride application were arranged.

At the 3-month follow-up, radiography was performed because of transient discomfort in the left posterior region, which showed dentin bridge formation under the pulp capping agent of tooth #75 (Fig. 2D) and no periapical abnormalities. At 18 months, the patient reported no discomfort, with improved oral hygiene, intact restorations/crowns, and normal radiographs (Fig. 2F).

3. Discussion

G6PD deficiency is an X-linked recessive genetic disorder characterized by acute hemolysis, jaundice, and anemia. These clinical manifestations arise from insufficient G6PD activity that disrupts the pentose phosphate pathway and reduces the production of nicotinamide adenine dinucleotide phosphate (NADPH), a critical molecule for maintaining red blood cell membrane integrity.[5,6]

In the absence of hemolytic triggers, G6PD-deficient patients remain asymptomatic, making diagnosis challenging during routine dental visits. Neonates presenting with severe hyperbilirubinemia, especially those of African, Mediterranean, or Southeast Asian descent, have a high likelihood of G6PD deficiency.[7] Therefore, pediatric dentists should maintain a high index of suspicion and conduct thorough medical history-taking when treating children from these ethnic groups to avoid iatrogenic hemolytic events.

For diagnosed patients, clinical severity is primarily determined by residual enzymatic activity. The patient presented with moderate G6PD deficiency and intermittent hemolytic episodes, which were predominantly triggered by infections or specific oxidative drugs.

The most important aspect of anesthetic management in patients with G6PD deficiency is minimizing oxidative stress to prevent hemolysis. Previous studies have confirmed the safety of propofol, remifentanil, and rocuronium in this population. However, the safety profile of certain anesthetic agents, including sevoflurane and midazolam, remains controversial. Although in vitro studies have demonstrated that sevoflurane can inhibit G6PD activity,[8] a growing body of clinical case reports has documented the safe administration of sevoflurane and isoflurane in G6PD-deficient patients.[5,9,10] To balance perioperative anesthetic efficacy and patient safety,[2,11] we used sevoflurane for gradual induction and combined propofol and remifentanil for maintenance in this case.

Given the need for pulp therapy, articaine was selected as the local anesthetic agent. Throughout the perioperative period, no signs of methemoglobinemia were observed, indicating that articaine was well



Fig. 1. Preoperative images of a 3-year-old boy with diagnosis of glucose-6-phosphate dehydrogenase deficiency. (A–C) Intraoral photographs demonstrate extensive caries in primary teeth. (D–G) Radiographs reveal multiple carious lesions in primary teeth without periapical abnormalities.

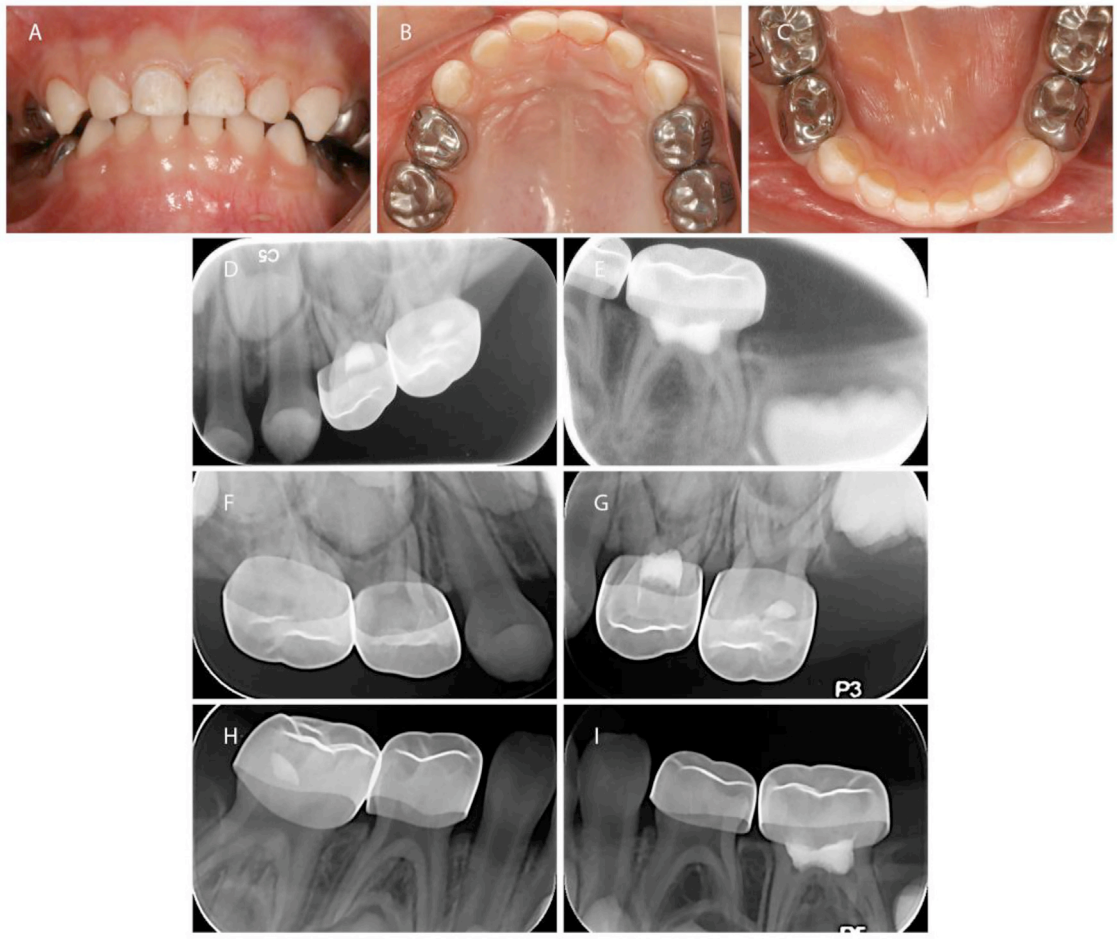

Fig. 2. Postoperative and follow-up images of a 3-year-old boy with diagnosis of glucose-6-phosphate dehydrogenase deficiency. (A–C) Postoperative intraoral photographs show resin composite restorations for primary anterior teeth and stainless steel crown for primary posterior teeth. (D–E) Radiographs at 3-month follow-up. (F–I) Radiographs at 18-month follow-up reveal no periapical abnormalities.

tolerated. It is worth noting that other local anesthetics, such as prilocaine and lidocaine, as well as topical anesthetics like benzocaine, have been reported to induce methemoglobinemia in G6PD-deficient individuals.[12,13] Goi *et al.*[14] reported the safe use of mepivacaine in a G6PD-deficient child undergoing dental treatment under general anesthesia, further emphasizing the importance of individualized anesthetic selection.

Postoperative analgesia is another critical consideration for G6PD-deficient patients. Najafi *et al.*[15] evaluated the hemolytic risk associated with short-term therapeutic doses of paracetamol, ibuprofen, tramadol, and parecoxib in G6PD-deficient children. Their findings indicated that short-term use of these medications did not increase the risk of hemolysis. Numerous other studies have also confirmed acetaminophen (paracetamol) as relatively safe for G6PD-deficient patients, whereas ibuprofen is commonly categorized as medium-risk.[2,16] Nevertheless, considering this patient's history of acetaminophen-induced hemolysis, we selected ibuprofen as the postoperative analgesic. Current evidence also supports the rationality of ibuprofen application, indicating that it can serve as a viable option for perioperative pain management in these children.[17] This highlights the necessity of personalized medication regimens based on individual medical histories.

Establishing a definitive causal relationship between a specific drug and the onset of hemolytic crisis in G6PD-deficient patients is often challenging due to interindividual pharmacokinetic and genetic variability; an agent that is safe for one patient may not be suitable for another.[7,18–20]

In addition to medications, infection is another common hemolytic trigger.[2,12,14] Quereshy *et al.*[21] reported cases of G6PD-deficient patients who developed hemolytic anemia secondary to maxillofacial infections caused by severely decayed teeth. Although our patient had no severe acute dental infection, multiple caries and incipient pulpitis would rapidly progress to periapical lesions and maxillofacial infections without timely intervention. Therefore, we completed full-mouth rehabilitation, provided standardized oral hygiene instruction for guardians, arranged regular follow-ups, and implemented quarterly professional fluoride application to block infection-related hemolytic triggers and prevent caries recurrence.

Hemolysis typically manifests 24–72 hours after trigger exposure[12,22] and general anesthesia may mask early signs.[2] Therefore, dentists should educate caregivers about the clinical manifestations of hemolytic anemia, which include sudden fever, nausea, vomiting, cyanosis, headache, fatigue, dyspnea, and dark urine.[2,23] Close postoperative follow-up is also crucial to monitor delayed hemolytic events. In the present case, the patient remained asymptomatic throughout the 1-week follow-up period, with no signs of hemolytic anemia. The successful outcome of this case was attributed to meticulous preoperative planning, multidisciplinary collaboration, careful selection of medications, and rigorous perioperative monitoring to avoid all hemolytic triggers.

In conclusion, this case demonstrates that detailed preoperative medical history screening and individualized perioperative management are essential for safe general-anesthesia-assisted dental treatment in pedi-

atric patients with G6PD deficiency. Low-oxidative-stress anesthetics, including propofol and remifentanil, are reliable and preferable for this patient population, and articaine can be safely adopted for local anesthesia in pediatric dental rehabilitation. Given the individual variability in drug-induced hemolytic reactions, medication selection must be personalized based on individual medical history rather than empirical unified regimens. Multidisciplinary collaboration and rigorous perioperative monitoring are crucial to reduce hemolytic and anesthetic complications, providing feasible clinical strategies for dental management of high-risk G6PD-deficient children.

Authors' contributions

Ma L and Zheng SY wrote the manuscript. Ma L and Zhang XH participated in clinical management of the patient. Wang XX and Wang S assisted in clinical management and collected clinical images and laboratory data. Ma L critically revised the manuscript and provided funding support. All authors have reviewed and approved the final version of the manuscript.

Patient's consent

Written informed consent has been obtained from the guardian for the publication of this case report.

Declaration of generative AI and AI-assisted technologies use

The authors declare that artificial intelligence tools have been used only for English language editing and manuscript formatting optimization in the drafting process of this article. The authors take full responsibility for the integrity and accuracy of all content in this article.

Conflicts of interest disclosure

The authors have no conflicts of interest to declare.

References

1. Luzzatto L, Bancone G, Dugué PA, et al. New WHO classification of genetic variants causing G6PD deficiency. *Bull World Health Organ*. 2024;102(8):615–617. doi:10.2471/BLT.23.291224.
2. Elyassi AR, Rowshan HH. Perioperative management of the glucose-6-phosphate dehydrogenase deficient patient: a review of literature. *Anesth Prog*. 2009;56(3):86–91. doi:10.2344/0003-3006-56.3.86.
3. Boonyuen U, Chuenchom P, Chaiyaratana W, et al. Improved genetic screening with zygosity detection through multiplex high-resolution melting curve analysis and biochemical characterisation for G6PD deficiency. *Trop Med Int Health*. 2025;30(5):437–457. doi:10.1111/tmi.14105.
4. Tan M, Liu X, Zhang Y, et al. Molecular epidemiological characteristics, variant spectrum and genotype-phenotype correlation of glucose-6-phosphate dehydrogenase deficiency in China: a population-based multicenter study using newborn screening. *PLoS One*. 2024;19(10):e0310517. doi:10.1371/journal.pone.0310517.
5. Cicvaric A, Miletic D, Hren J, et al. Management of anesthesia and perioperative procedures in a child with glucose-6-phosphate dehydrogenase deficiency. *J Clin Med*. 2022;11(21):6476. doi:10.3390/jcm11216476.
6. Luzzatto L, Ally M, Notaro R. Glucose-6-phosphate dehydrogenase deficiency. *Blood*. 2020;136(11):1225–1240. doi:10.1182/blood.2019000944.
7. Jeon J, Yang S, Choi NK, et al. Dental management in a child patient with glucose-6-phosphate dehydrogenase deficiency: a case report. *J Korean Acad Pediatr Dent*. 2021;48(3):359–366. doi:10.5933/JKAPD.2021.48.3.359.
8. Altikat S, Ciftci M, Buyukokuroglu ME. In vitro effects of some anesthetic drugs on enzymatic activity of human red blood cell glucose 6-phosphate dehydrogenase. *Pol J Pharmacol*. 2002;54(1):67–71. doi:10.1177/023970490205400110.
9. Dairi AS, Dairi G, Farghaly MA. Anesthetic management in a patient with glucose-6-phosphate dehydrogenase deficiency undergoing coblation adenoidectomy with septoplasty and turbinectomy. *J Med Cases*. 2019;10(10):293–295. doi:10.14740/jmc3371.
10. Valiaveedan S, Singh S, Bhatia P, et al. Anaesthetic management in patients with glucose-6-phosphate dehydrogenase deficiency undergoing neurosurgical procedures. *Indian J Anaesth*. 2011;55(1):68–70. doi:10.4103/0019-5049.76597.
11. Sharma V, Kaur J, Singh G, et al. Propofol infusion in an infant with glucose-6-phosphate dehydrogenase deficiency. *J Anaesthesiol Clin Pharmacol*. 2018;34(1):136–137. doi:10.4103/joacp.JOACP_112_16.
12. Munasinghe BM, Nimalan S, Subramaniam N, et al. Anesthesia for a child with glucose-6-phosphate-dehydrogenase deficiency: a case report. *Int J Sci Rep*. 2020;6(12):526–528. doi:10.18203/issn.2454-2156.IntJSciRep20205032.
13. Moretti S, Jouvet P, Schleiermacher G, et al. Pulse oximetry and methemoglobinemia. *Arch Pediatr*. 1996;3(3):258–260. doi:10.1016/0929-693x(96)81305-4.
14. Goi T, Tanaka T, Sato M, et al. General anesthesia in a glucose-6-phosphate dehydrogenase deficiency child: a case report. *Anesth Prog*. 2019;66(2):94–96. doi:10.2344/anpr-66-01-05.
15. Najafi N, Van de Velde A, Poelaert J. Potential risks of hemolysis after short-term administration of analgesics in children with glucose-6-phosphate dehydrogenase deficiency. *J Pediatr*. 2011;159(6):1023–1028. doi:10.1016/j.jpeds.2011.05.056.
16. Beutler E. Acetaminophen and G-6-PD deficiency. *Acta Haematol*. 1984;72(3):211–212. doi:10.1159/000206390.
17. Pankey AN, Chandar A, Isaacson G. Safety of ibuprofen in children with G6PD deficiency: a systematic review. *Laryngoscope*. 2022;132(6):1300–1305. doi:10.1002/lary.29868.
18. Gammal RS, Pirmohamed M, Somogyi AA, et al. Expanded clinical pharmacogenetics implementation consortium guideline for medication use in the context of G6PD genotype. *Clin Pharmacol Ther*. 2023;113(5):973–985. doi:10.1002/cpt.2735.
19. Bubp J, Jen M, Matuszewski K. Caring for glucose-6-phosphate dehydrogenase (G6PD)-deficient patients: implications for pharmacy. *P T*. 2015;40(9):572–574.
20. Gronich N, Rosh B, Stein N, Saliba W, et al. Medications and acute hemolysis in G6PD-deficient patients—a real-world study. *Clin Pharmacol Ther*. 2024;116(6):1537–1543. doi:10.1002/cpt.3333.
21. Quereshy FA, Gold ES, Powers MP. Hemolytic anemia in a glucose-6-phosphate dehydrogenase-deficient patient triggered by a maxillofacial infection. *J Oral Maxillofac Surg*. 2000;58(7):805–807. doi:10.1053/joms.2000.7273.
22. Takahashi N, Matsumoto S, Tanaka Y, et al. Dexmedetomidine-based intravenous anesthesia of a pediatric patient with glucose-6-phosphate dehydrogenase (G6PD) deficiency: a case report. *Med (Baltim)*. 2017;96(21):e6986. doi:10.1097/MD.0000000000006986.
23. Hernández-Pérez D, Butrón-Téllez Girón C, Ruiz-Rodríguez S, et al. Dental considerations in children with glucose-6-phosphate dehydrogenase deficiency (Favism): a review of the literature and case report. *Case Rep Dent*. 2015;2015:506459. doi:10.1155/2015/506459.